

Domestic Violence: No Place for a Smile

Casey Gwinn, JD; George E. McClane, MD;
Kathleen A. Shanel-Hogan, DDS, MA; and
Gael B. Strack, JD

ABSTRACT

Because dentists routinely assess a patient's head, neck and mouth, they have a unique and excellent opportunity to recognize whether or not a patient is being abused.

This article seeks to enlist the collaboration of the dental community in the effort to prevent domestic/intimate partner violence and provide more information about the signs and symptoms of domestic violence injuries, including strangulation, which is often overlooked by medical and dental professionals. Strangulation has only been identified in recent years as one of the most lethal forms of domestic violence. Unconsciousness may occur within seconds and death within minutes. It is known that victims may have no visible injuries whatsoever yet because of underlying brain damage by a lack of oxygen from being strangled, victims may have many serious internal injuries or die days or several weeks later.

Strangulation is often indicative of a high level of domestic violence in a relationship. Attempted strangulation may cause physiological changes evident in the course of a dental examination. For these reasons, dentists should be vigilant in looking for its symptoms.

PURPOSE OF PAPER

Despite our collective efforts, domestic violence continues to be a problem. A missing ingredient is a strong partnership with the dental community. The legal community needs the expertise of the dental community to detect and document domestic violence injuries. Victims need support and referrals from their dentists. Early detection and intervention can save lives.

This article seeks to enlist the help of the dental community and provide more information about the signs and symptoms of domestic violence injuries, including strangulation, which is often overlooked by medical and dental professionals.

It was the loose tooth that caused Samantha to seek out her dentist. If the tooth fell out, she would have to explain what happened to her co-workers. She wasn't ready to tell, at least not yet. As she drove to the dentist's office, she practiced her story: She fell while trying to change the bathroom light bulb. Makeup would conceal the rest. The pain in her throat and the difficulty swallowing, no one would notice that. If only she hadn't resisted so much when her husband tried to choke her. But the minute Samantha checked in, the receptionist knew something wasn't right. It may have been the aimlessness with which she walked, the sadness in her eyes, or maybe the resignation in her voice. Her dentist sensed something too. Her voice sounded hoarse and a lit-



Authors / Casey Gwinn, JD, is the city attorney for San Diego.

George E. McClane, MD, is an emergency physician at Sharp Grossmont Hospital and medical director for San Diego Justice Center's Forensic Medical Unit.

Kathleen A. Shanel-Hogan, DDS, MA, is a consultant, educator, facilitator and family violence prevention advocate. She works with the California Dental Association Foundation as a consultant and a mandated reporter training in all forms of family violence. She is author of the Dental Professionals Against Violence Program.

Gael B. Strack, JD, is assistant city attorney for San Diego.



tle raspy. Beneath her makeup, he noticed a rash and a thumb-sized bruise on her neck. This was not the first time he had noticed injuries that seemed inconsistent with her explanations and certainly not the first time that Samantha refused to smile. But this time, things seemed more serious. To the dentist the injuries suggested violence, possibly even attempted strangulation. What should he do? Should he say something to Samantha? To someone else? Did his suspicions put him under any sort of legal obligation?

Domestic violence leaves no room for a smile — not in one's home, at work, or even in a dentist's office. Domestic violence is now recognized as one of the nation's most pressing women's health problems.¹ The Centers for Disease Control and Prevention reports that the health-related costs of intimate partner violence against women exceed \$5.8 billion annually in the U.S. The cost to the criminal justice system (police, prosecutors, the courts — civil, juvenile and criminal) has yet to be calculated. It is estimated that nearly 4 million women each year suffer domestic violence.² When battered women are severely injured, they seek help. They seek help from police officers and their health care professionals, including their dentist. Between 22 percent and 35 percent of women's visits to hospital emergency departments are prompted by injuries or illness related to ongoing abuse or stress from such abuse.³ The literature reports 36 percent to 95 percent of battered women are suffering injuries to the face, neck or head.⁴ It is important to also recognize that men or women can be battered by intimate partners of either sex. Dentists naturally observe a patient's head, neck and mouth. As such, dentists have a unique opportunity to recognize whether or not a patient is being abused.

Over the last 20 years, due to heightened awareness, both the health care and criminal justice system have

addressed the issue of domestic violence. Health care professionals have also become increasingly involved in the fight against domestic violence. In 1985, former U.S. Surgeon General C. Everett Koop brought national attention to domestic violence as a public health problem.⁵ The surgeon general stated:

"Identifying violence as a public health issue is a relatively new idea.

Because dentists routinely assess a patient's head, neck and mouth, they have a unique and excellent opportunity to recognize whether or not a patient is being abused.

Traditionally, when confronted by the circumstances of violence, the health professions have deferred to the criminal justice system ... [Today] the professions of medicine, nursing and the health-related social services must come forward and recognize violence as their issue."⁶

Dentists can play a key role in the fight against domestic violence

Because dentists routinely assess a patient's head, neck and mouth, they have a unique and excellent opportunity to recognize whether or not a patient is being abused. One of "the most important contributions physicians can make to ending abuse and protecting the health of its victims is to identify and acknowledge the abuse," according to the Council on Ethical and Judicial Affairs, AMA, 1992. Dr. Ellen Taliaferro

finds that although some controversy exists regarding the need for screening and which methods of screening are best, it is prudent to offer some form of screening to all patients presenting to the health care system. This can be done by direct clinician inquiry, patient health questionnaires or system query in the form of posters and information available for distribution. Effective screening sets the stage for intervention and successful intervention sets the stage to break the cycle of violence.⁷

In a recent survey conducted by the UCSF School of Dentistry, it was found that many dentists currently don't screen for, or even report, signs of domestic violence, but more than half the dentists surveyed said they would like more training in this area. Aside from a lack of proper education in detection of the clinical signs and symptoms of human abuse,⁸ the UCSF researchers found other reasons for the lack of screening: the presence of family members during the visit; concerns about offending the patient and the dentist's own embarrassment when talking to the patient.

Under California law, health care providers must report suspected or known domestic violence due to physical assault to local police by telephone immediately and in writing within 48 hours.⁹ Dentists, registered dental hygienists, and registered dental assistants are mandated reporters and are required to report. Failure to report domestic violence exposes the health care provider to a misdemeanor which is punishable by a maximum \$1,000 fine and/or six months in county jail. Not only is the failure to report a violation of law, it also makes it more difficult for the dentist to defend against potential civil lawsuits. More importantly, failing to report suspected or known instances of domestic violence represents a missed opportunity to assist the patient in escaping an abusive relationship.

There is some controversy regarding the efficacy of screening and reporting

laws but this is not the subject of this article. Rather, this article is intended to inform health care providers that they are subject to the law and that they must follow the law's relatively straightforward reporting requirements. In fact, 45 states have laws that mandate reports of injuries caused by weapons, crimes or domestic violence.¹⁰ At least one study has shown that mandatory reporting laws do not deter patients from seeking medical care.¹¹ Researchers using both simple interview techniques and questionnaires in medical surroundings have found that identification of domestic violence is not difficult.¹² Also, in many cases women do talk quite frankly about causal factors when asked directly and often battered women are waiting for someone to do just that.¹³ The dental professional often has established trust with the patient and appointments are often 45 minutes to 90 minutes long. The research indicates that by asking a few well-placed questions, dentists can confirm the presence of domestic violence and set the stage for positive intervention in the lives of battered women.

It is true for all victims and it is true for victims in dentists' offices: "[I]dentification of domestic violence is the first stage of intervention. Asking about abuse helps to break the isolation a battered woman may experience and lets her know resources are available if and when she feels she can use them."¹⁴ In a study of how physicians helped victims of domestic violence, UCSF researchers found that physicians who provided validation — acknowledged that the abuse had occurred and confirmed the patient's worth — had a positive impact on patients. The study found validating messages such as "battering is wrong" and "you deserve better treatment" not only provided relief and comfort to women, but also helped them realize the seriousness of their situation and helped them move forward toward safety.¹⁵ A dentist who recognizes the signs of domestic violence and is willing to offer

understanding and support — even within the limited confines of an office visit — can provide a much-needed measure of hope for the battered woman. Because a battered woman is subject to an intense level of emotional degradation on an almost daily basis, a few words of encouragement may help her to begin to re-evaluate her relationship and possibly move her beyond the violence.

By asking a few well-placed questions, dentists can confirm the presence of domestic violence and set the stage for positive intervention in the lives of battered women.

In any event, it is unlikely she will forget the intervention.¹⁶

In the absence of intervention, battering tends to recur with increasing frequency and severity.¹⁷ To safeguard victim safety, Warshaw and Ganley recommend that health care providers should inform patients of their legal obligation to report if domestic violence is indicated.¹⁸ It is recommended that before making a report, a concerned dentist should explain that the consequences of the report may include a law enforcement response. Asking the patient to participate in the telephone call to make the report can facilitate a dialogue between the patient and law enforcement. The response can then work collaboratively with the patient regarding timing and type of response with attention to the safety of the patient and any children. Dentists should also have available an

updated list of local domestic violence service agencies¹⁹ and other community resources to give to battered patients. Materials from Dental Professionals Against Violence (DPAV) can assist the dental professionals in preparing a protocol for the dental offices. For more information contact DPAV at the California Dental Association Foundation (916) 443-3382, ext. 8900.

Dr. Barbara Gerbert, who is a UCSF professor and chair of the Division of Behavioral Sciences in the School of Dentistry, suggests a model in which dentists ask patients about abuse. Give validating messages which acknowledge that battering is wrong and which confirm the patient's worth; document signs, symptoms and disclosures in writing and with photographs; and refer victims to domestic violence specialists in the community.

While detection of domestic violence injuries is generally not difficult, it does require the healthcare professional to be perceptive. There is a tendency of abused patients to minimize domestic violence and/or hide their injuries. For this reason, it is important to review the obvious signs of injuries as well as the subtler signs and symptoms of strangulation.

Domestic Violence Injuries

The head, face and neck are the most frequent places injury is received during domestic violence. There is also evidence to suggest that male attackers may tend to avoid striking the face so that injuries will not be apparent to onlookers; instead, a blow to the back of the head may be more common.²⁰ Drs. Salber and Taliaferro have identified the following injuries as characteristic of domestic violence.²¹

- Bilateral injuries, especially to the extremities
- Injuries at multiple sites
- Fingernail scratches, cigarette burns and rope burns
- Abrasions, minor lacerations or welts

STRANGULATION



- Pattern injuries such as bite marks; marks from jewelry, belts or keys; or designs or patterns stamped or imprinted on or immediately below the epithelium by weapons

- Injuries that are inconsistent with the victim's explanation

- Multiple injuries in various stages of healing

- Injuries during pregnancy

The typical bite mark, according to Dr. Sperber, is a "round or oval, ring-shaped injury consisting of two facing arches, each made up a series of aligned contusions, abrasions and/or lacerations. The center injury measures 3 cm to 4 cm. The individual markings comprising the arches represent the biting surfaces of front teeth distributed around the upper and lower jaws."

There are also variations in the pattern.²²

- Central ecchymosis — contusion within the center of the bite mark caused by capillary bleeding. It occurs as a result of compression of tissue by the teeth with or without suction.

- Drag marks — radiating, linear contusions or abrasions at the periphery of the mark indication of scraping of teeth along the skin as the bite occurred.

- Avulsed bite mark — when the bitten tissue is torn off, leaving a central lacerated defect.

- One arched bite mark — rare, but may occur.

- Half-bite mark — when only the right or left side of a bite mark shows up.

- Double-bite mark — bite mark within a bite mark. Occurs when skin is bitten, then starts to slip out between teeth and is bitten again.

- Overlapping bite marks — multiple, separate bite marks made repeatedly in the same general location.

- Toothless bite mark — shows a contused ring of compatible size and curvature but without well-defined, individual tooth marks. Occurs in healing bite marks and bite marks on soft or fatty skin.

Typical domestic violence injuries

that may be detected by a dentist²³ are:

- Intraoral bruises from slaps, hits and soft tissue pressed on hard structures like teeth and bones.

- Soft and hard palate bruises and abrasions from implements of penetration could indicate force from a sexual act.

- Fractured teeth, nose, mandible and/or maxilla. Signs of healing fractures may be detected in panoramic radiographs.

- Abscessed teeth could be from tooth fractures or repeated hitting to one area of the face.

- Torn frenum (a fold of membrane

Attempted strangulation may cause physiological changes evident in the course of a dental examination.

which checks or restrains the motion of a part, such as the fold on the underside of the tongue or upper lip) from assault or forced trauma to the mouth.

- Hair loss from pulling, black eyes, ear bruises, other trauma and lacerations to the head.

The Signs and Symptoms of Attempted Strangulation

Strangulation has only been identified in recent years as one of the most lethal forms of domestic violence. Unconsciousness may occur within seconds and death within minutes.²⁴ It is known that victims may have no visible injuries whatsoever, yet because of underlying brain damage by a lack of oxygen from being strangled, victims may have many serious internal injuries or die days or several weeks

later.²⁵ Strangulation is often indicative of a high level of domestic violence in a relationship. Attempted strangulation may cause physiological changes evident in the course of a dental examination. For these reasons, dentists should be vigilant in looking for its symptoms.

In a study conducted by the San Diego City Attorney's Office of 300 domestic violence cases, visible injuries such as tiny red spots on the face, bloody red eyes, red marks, scratches and bruising on the neck, were only visible 16 percent of the time.²⁶ Often, when visible injuries were present, the injuries were subtle and hard to find. The study disclosed other symptoms. To understand the medical significance of the findings from the study, the city attorney's office enlisted the help of George McClane, an emergency physician, and Dean Hawley, a specialist in forensic pathology, for their medical perspective.

The Medical Perspective

Strangulation is defined as a form of asphyxia characterized by closure of the blood vessels and/or air passages of the neck as a result of external pressure on the neck.^{27,28} The three forms of strangulation are hanging, ligature, and manual. Almost all attempted or actual homicides by strangulation involve either ligature or manual strangulation. Ten percent of violent deaths in the U.S. each year are due to strangulation, six females to every male.

Ligature strangulation is strangulation with a cord-like object (also referred to as garroting), and may include anything from a telephone cord to articles of clothing.^{29,30} Manual strangulation or throttling is usually done with the hands, but notable variants include using the forearms (as when police officers use the carotid restraint) to standing or kneeling on the victim's throat.^{31,32} Manual self-strangulation is not possible, because when the individual loses consciousness, pressure can no longer be applied.

A review of neck anatomy is critical

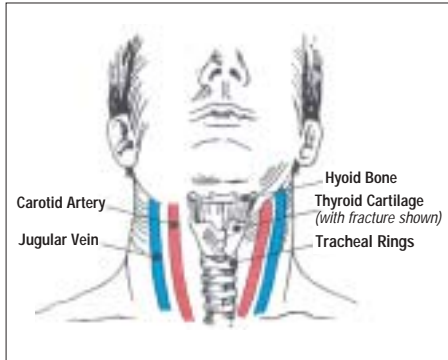


Figure 1. Anatomy illustration of the neck.

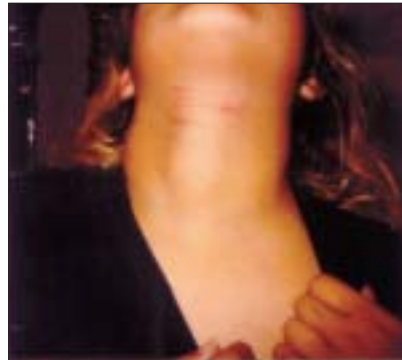

Figure 2. These markings may have been caused by the victim's fingernails in an attempt to remove a chokehold. They also may be caused by the assailant adjusting their hands and applying force during a vigorous struggle. The webbing between the thumb and index finger can produce the linear lesions shown.

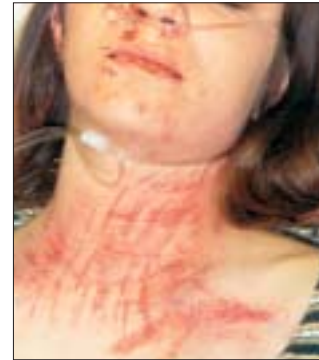

Figure 3. Classic abrasions caused by victim's own nails while attempting to remove assailant's hands or ligature. The vertically oriented pattern demonstrates bicep muscle strength at its best advantage in this defensive maneuver.

in order to understand adequately the clinical features of a strangled victim. The hyoid bone, a small horseshoe-shaped bone in the neck, helps to support the tongue. The larynx, made up of cartilage, not bone, consists of two parts: the thyroid cartilage (so-called because it is next to the thyroid gland) and the tracheal rings.

Carotid arteries are the major vessels that transport oxygenated blood from the heart and lungs to the brain. These are the arteries at the side of the neck that persons administering cardio-pulmonary resuscitation check for pulses. Jugular veins are the major vessels that transport deoxygenated blood from the brain back to the heart (**Figure 1**).

The general clinical sequence of a victim who is being strangled is one of severe pain, followed by unconsciousness, then brain death. The victim will lose consciousness by any one or all of the following: blocking of the carotid arteries (depriving the brain of oxygen), blocking of the jugular veins (preventing deoxygenated blood from exiting the brain), and closing off the airway, causing the victim to be unable to breathe.

Only 11 pounds of pressure placed on both carotid arteries for 10 seconds is necessary to cause unconsciousness.³³ However, if pressure is released immedi-

ately, consciousness will be regained within 10 seconds. To completely close off the trachea, three times as much pressure, 33 pounds, is required. Brain death will occur in four to five minutes, if strangulation persists.

Signs and Symptoms

Symptomatic voice changes will occur in up to 50 percent of victims, and may be as mild as simple hoarseness or as severe as complete loss of voice.³⁴ Swallowing changes are due to injury of the larynx cartilage and/or hyoid bone. Swallowing may be difficult but not painful, or painful. Breathing changes—normally the result of the hyperventilating that goes hand in hand with a terrifying event—may more significantly be the result of an underlying neck injury. The victim may find it difficult to breathe (dyspnea) or may be unable to breathe (apnea). It is critical to note that breathing changes following an attempted strangulation may be subtle or mild. However, the, underlying injuries may kill the victim up to 36 or more hours later due to the decompensation of the underlying injured structures. Because dentists are unlikely to see the victims of attempted strangulation until hours or days after the event, they should be especially watchful for labored breathing.

Behavioral changes may manifest early as restlessness and combativeness due to temporary brain anoxia and/or severe stress reaction, and subsequent resolve.³⁵ While dentists may not have the opportunity to observe these early symptoms, changes can also be long-term, resulting in frank psychosis and amnesia.

Visible injuries to the neck include scratches, abrasions, and scrapes. These may be from the victim's own fingernails as a defensive maneuver, but commonly are a combination of lesions caused by both the victim and the assailant's fingernails.

Lesion location varies depending on whether the victim or assailant used one or two hands, and whether the assailant strangled the victim from the front or back. Three types of fingernail markings may occur, singly or in combination: impression, scratch, or claw marks (**Figure 2**).

Impression marks occur when the fingernails cut into the skin; they are shaped like commas or semi-circles. Scratch marks are superficial and long, and may be narrow or as wide as the fingernail itself. Claw marks occur when the skin is undermined; they tend to be more vicious and dramatic appearing^{36,37,38} (**Figure 3**).

Because most victims are women, the

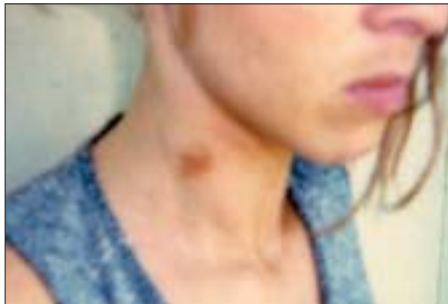

Figure 4. Often, when a single bruise is the sole finding on a victim's neck, it may be caused by the assailant's thumb as this opposing digit has the greatest vector force in a human grip. It may or may not manifest up to 24 hours after the assault took place.

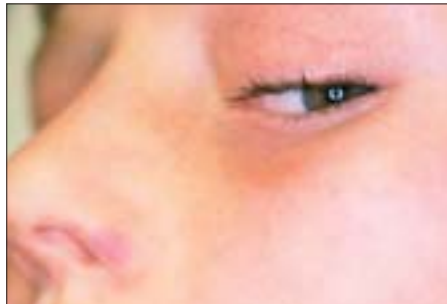

Figure 5. Diffuse petechiae with a confluent pattern found on upper eyelid of a young child strangled by an adult male. Due to a thin dermal layer, the eyelids are among the most susceptible tissue to manifest visible petechiae on both the external and internal surfaces.

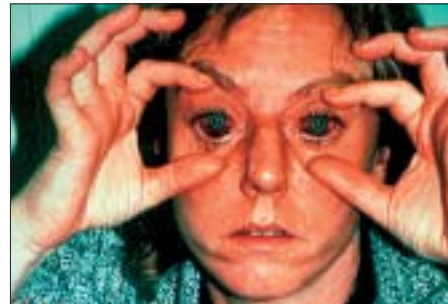

Figure 6. Subconjunctival hemorrhages are essentially confluent petechiae caused by the rupture of the capillaries in the ocular sclerae bursting from venous back up due to external pressure placed upon the jugular veins. Though dramatic, they are painless, harmless and resolve in a matter of days.

scratches caused by their longer nails frequently are more severe than the scratches caused by the assailant. Claw marks may be grouped, parallel markings vertically down the front of the neck, but often are scattered in a random fashion.

Redness on the neck may be fleeting, but may demonstrate a detectable pattern.³⁹ These marks may or may not darken to become a bruise. Bruises may not appear for hours or even days. Fingertip bruises are circular and oval, and often faint. A single bruise on the neck is most frequently caused by the assailant's thumb⁴⁰ (Figure 4).

However, bruises frequently may run together, clustering at the sides of the neck, as well as along the jaw lines, and may extend onto the chin, and even the collar bones.

Chin abrasions are also common in victims of manual strangulation, as the victim lowers the chin in an instinctive effort to protect the neck, and in so doing, scrapes the chin against the assailant's hands. It is important that a dentist document visible injuries to the neck and face; photographs are an especially effective form of evidence.

The tiny red spots, petechiae, characteristic of many cases of strangulation are due to ruptured capillaries — the smallest blood vessels in the body — and sometimes may be found only under the eyelids (conjunctivae).⁴¹ However, sometimes

they may be found around the eyes in the peri-orbital region, anywhere on the face, and on the neck in and above the area of constriction (Figure 5).

Petechiae tend to be most pronounced in ligature strangulation.⁴² Blood-red eyes are due to capillary rupture in the white portion of the eyes (Figure 6). This phenomenon suggests a particularly vigorous struggle between the victim and assailant.

Ligature marks such as rope burns may be very subtle, mimicking the natural folds of the neck. They may also be much more dramatic, reflecting the type of ligature used, e.g., the wave-like form of a telephone cord, or the braided pattern of a rope or clothesline. If the victim has been strangled from behind, the impression from the ligature generally will be horizontally oriented at the same level of the neck.

Swelling of the neck may be caused by any one or combination of the following: internal bleeding,⁴³⁻⁴⁵ injury of any of the underlying neck structures, or fracture of the larynx allowing air to escape into the tissues of the neck.

Last, victims may have no visible injuries whatsoever, with only transient symptoms — yet because of underlying brain damage by lack of oxygen during strangulation, victims have died up to several weeks later.⁴⁶ Because of these unforeseen consequences of injuries

from a strangulation attempt that may appear minor, dentists should encourage a medical evaluation of all victims who report being strangled or "choked."

At the Forensic Medical Unit located at the San Diego Family Justice Center, the accompanying form (see page 408) is used for the documentation of strangulation injuries. Dentists are encouraged to use this form, or an equivalent, if they suspect or know a patient has been subjected to attempted strangulation.

Small Window of Opportunity

The window of opportunity to intervene in domestic violence cases is short. Depending on the victim, her willingness to tell the truth may last only minutes and usually no more than a few days. She may also be experiencing guilt, one of four characteristics of the Battered Woman Syndrome⁴⁷ — guilt, denial, enlightenment or responsibility. For this reason, a dentist who suspects domestic violence needs to work fast and intervene as quickly as possible. Recognize that by the time a woman seeks dental care for her injuries, she may have had further contact with the batterer and may already be entering the "honeymoon phase." Accordingly, a dentist should not be surprised if the patient refuses to admit to any violence and attempts to describe her injuries as the result of an accident.

Even when the victim denies that

domestic violence is taking place, this is a good opportunity to ask the victim if she feels safe and if she believes it is OK to be abused. Usually victims will respond: "No, it's not OK." If this is the response, another follow up question could be: "What would you like to see done?" or "How can the behavior be stopped?" This discussion helps the victim understand why police and prosecutors need to go forward in order to stop abusive behavior even if she does not to participate in the criminal proceedings. It also helps victims understand that police and prosecutors are trying to help.⁴⁸

By understanding why victims deny that domestic violence is taking place, dentists will be able see through the victim's "protection mechanism," and develop supportive and compassionate interviewing skills which will elicit truthful information as opposed to "shutting" her down.

Documentation

Documentation is key to a successful intervention. When accurately and objectively documented, documentation of domestic violence incidents can be useful for criminal prosecution as well as civil cases. Language is critical. Personal beliefs, biases or prejudices should never appear in a medical record. As an example, the following phrase casts doubt on the victim's credibility: "the patient claims that her boyfriend hit her" as opposed to "the patient stated "I was hit by my boyfriend."

Even if victims are initially reluctant to report, she may later want to pursue legal remedies. She may also change her mind. Documentation of past incidents will help either a criminal or civil case,⁴⁹ especially if that documentation is absent of bias.

Even when victims recant or become unavailable for trial, prosecutors can still proceed with prosecution without the victim's testimony through what is now commonly referred to as evidence-based prosecution. From the dentist's perspec-

tive evidence-based prosecution⁵⁰ simply means documenting the demeanor, description and physical condition of the victim — including injuries or lack of injuries; identity of the reporting party; the party's dental treatment; obtaining a medical release from the victim to later corroborate her injuries; and any other information — such as the identity of the abuser — that the victim is willing to provide that will assist in the prosecution of the batterer.

For purposes of mandated reporting under California Penal Code section 11161, mandated reporters are required to provide the following:

Personal beliefs, biases or prejudices should never appear in a medical record.

- The name of the injured person, if known.
- The injured person's whereabouts.
- The character and extent of the person's injuries.
- The identity of the person who inflicted the wound, other injury, or assaultive or abusive conduct upon the injured person.

Penal Code Section 11161 further recommends the following additional information be included in medical records:

- Include any comments by the injured person regarding past domestic violence and the name of the abuser.
- Map of the injured person's body showing and identifying injuries and bruises at the time of the health care visit.
- Copy of the law enforcement reporting form.

The authors recognize the typical dentist's office may not be equipped with special domestic violence forms, body maps and/or a camera to document additional information about domestic violence. The good news is today there are many resources for medical professionals to improve their documentation.⁵¹ There is no need to reinvent the wheel. The Family Violence Prevention Fund has developed health kits which may be easily obtained via Web site www.fvpf.com to address the issue of domestic violence in the dental office. Included in this issue is a copy of Sacramento County's Intimate Violence Mandated Report Form developed through the collaboration of all the healthcare systems in Sacramento, the dental community, law enforcement, justice system, and fire/EMS departments. Domestic violence professionals such as police officers, prosecutors and/or advocates, are frequently available to provide training and other materials that contain information about local resources. Often, a single phone call to a local domestic violence shelter can provide a wealth of phone numbers from which additional resources and professionals can be located. And, DPAV provides continued training and support of dental professionals to recognize, respond and report domestic violence situations as well as child abuse/neglect and dependent and elder abuse/neglect. For more information contact DPAV at the California Dental Association Foundation (916) 443-3382, Ext. 8900.

As a general rule, documentation of domestic violence injuries will generally result in the quicker disposition of cases in court without requiring a health care provider's in-court testimony. More importantly, clear documentation can greatly increase victim safety and offender accountability. By providing complete, objective and bias-free documentation in dental records, dentists can substantiate a victim's account of the incident⁵² and make available more accurate data. The data in turn lays the groundwork for effective prevention strategies, improved



policies and legislation. Patient charting is the essential first step toward injury prevention.⁵³ Structured charting may provide yet more complete data collection.^{54,55} The dental chart reflects collected information and data regarding incidents of trauma, routine examinations, and treatments that often include charting of the soft and hard tissues of the head and neck. Periapical radiographs of individual teeth and panoramic radiographs of the head may be available for pre- or post-trauma comparison. If the patient has had restorative or orthodontic treatment, available plaster or stone study models may demonstrate pre-trauma conditions. Intraoral photographs may document structures prior to trauma. If trauma is demonstrated inside the mouth, intraoral color photography provides documentation. Extraoral photographs may be available also.

Conclusion

Efforts have improved identification, documentation, professional education, forensic examination, community prevention efforts and funding of services for victims of domestic violence.⁵⁶ California now boasts sophisticated responses to domestic violence from domestic violence response teams; vertical units in police departments or prosecutor's office, specialized courts, the California Medical Training Center and Family Justice Centers in San Jose and San Diego which houses the Forensic Medical Unit sponsored by Sharp Grossmont Hospital. The CDA Foundation with funding from Blue Shield Foundation and Dental Benefit Providers has expanded the previous PANDA efforts to become DPAV to educate dental professionals, other mandated reporters, and foster community collaboration.

If battered victims with injuries seek help from the legal and medical system, then it is clear that the dental and legal communities must work more closely together. By developing strong partnerships, we can restore the smiles of victims

and their children. The time has come for the dental and legal professions to share their expertise and work more closely with other domestic violence prevention professionals. No single group can do it alone. Together we can! **CDA**

To request a printed copy of this article, please contact / Gael Strack, assistant city attorney, San Diego City Attorney's Office, Family Justice Center, 707 Broadway, Suite 7900, San Diego, Calif., 92101.

References / 1. Sheridan D, Treating survivors of intimate partner abuse: Forensic identification and documents. *Forensic Emerg Med* 203-28, 2001.

2. Novella A, From the surgeon general, U.S. Public Health Service. *JAMA* 276(23):31-2, 1992.

3. Randalaa T, Domestic violence intervention calls for more than treating injuries. *JAMA* 264: 939-40, 1990.

4. Ochs HA, Neuenschwander MC, Dodson TB., Are head, neck and facial injuries markers of domestic violence? *J Am Dent Assoc* 127(6): 757-61; *Family Dent*, www.cincytoothdoc.com, June 1996.

5. Koop CE, Foreword. *Violence in America: A public health approach*. Ed. ML Rosenberg. New York: Oxford University Press, 1991.

6. Flitcraft, A., Physicians and domestic violence: Challenges for prevention. *Health Aff* 154-5, 1993.

7. Taliaferro E, Screening and identification of intimate partner violence. *Clin Fam Pract* 5(1): 89, 2003.

8. Dr. Rajiv Khosla's Web site, www.geocities.com/drkhosla1/news/news61.html: See also *Fam Dent*, the Loewe and Wright Way, www.cincytoothdoc.com.

9. California Penal Code section 11160.

10. Houry D, Sachs C, Feldhaus K, Lindon J, Violence-inflicted injuries: Reporting law in the fifty states. *Ann Emerg Med* 39:1, 2002.

11. Houry D, Feldhaus K, Thorson AC, et al. Mandatory laws do not deter patients from seeking medical care. *Ann Emerg Med* 34: 336-41, 1999.

12. Robertson J, Domestic violence and health care: An ongoing dilemma. *Albany Law Review* 68:1199, 1995.

13. Ibid.

14. Warshaw C, Ganley A, *Improving the Health Care Response to Domestic Violence: A Resource Manual for Health Care Providers* published by the Family Violence Prevention Fund 2(7): 64.

15. www.ucsf.edu/today/.

16. Robertson J, Domestic violence and health care: An ongoing dilemma. *Albany Law Review* 68:1207.

17. Stark E, Mandatory arrest of batterers: A reply to its critics. *Am Behav Scientist* 36(5):651-80, 1993.

18. Warshaw, C, Ganley A, *Improving the Health Care Response to Domestic Violence: A Resource Manual for Health Care Providers* published by the Family Violence Prevention Fund, 2(9): 75.

19. Dentists can obtain information about their law enforcement response to domestic violence by calling their local police department or local shelter, as well as the Commission on Police Officer's Standards (POST); California District Attorney's Association; Statewide California Coalition for Battered Women; National Domestic Violence Hotline.

20. Corrigan J, Wolf M, Mysiw U, Jackson R, Bogner J, Early identification of mild traumatic

brain injury in female victims of domestic violence. *Am J Obstet Gynecol* 188: S71-6, 2003.

21. Salber P, Taliaferro E, *The Physician's Guide to Domestic Violence* 5: 57-9. Volcano Press, 1995.

22. Sperber N, Bite mark evidence in crimes against persons, *FBI Law Enforcement Bulletin*.

23. Shanel-Hogan KA, Jarrett JA, Dentistry as a collaborative partner in domestic violence recognition, Home Front, California District Attorneys' Association, Winter 2000; See also educational program Dental Professionals Against Violence through the California Dental Association Foundation (916) 443-3882 ext 8900; *Manual of Forensic Odontology* published by the ASFO and *Forensic Dentistry* published by CRC Press in Boca Raton, Fla.

24. Smith D, Mills T, Taliaferro E, Violence: Recognition, management and prevention, frequency and relationship of reported symptomatology in victims of intimate partner violence: The effect of multiple strangulation attacks. *J Emerg Med* 21:3: 323-29, 2001.

25. Hawley D, McClane G, Strack G, Violence: Recognition, management and prevention. A review of 300 attempted strangulation cases part III: Injuries in fatal cases. *J Emerg Med* 21(3): 317-22, 2001.

27. Strack G, McClane G, Hawley D, Violence: Recognition, management and prevention. A review of 300 attempted strangulation cases part I: Criminal legal issues. *J Emerg Med* 21(3): 303-9, 2001. Line, WS Jr, Stanley RB Jr, Choi JH, Strangulation: a full spectrum of blunt neck trauma. *Ann Otol Rhinol Laryngol* 94(6:1): 542-6, Nov. 1985

28. Iserson, KV, Strangulation: a review of ligature, manual, and postural neck compression injuries. *Ann Emerg Med* 13:3, 179-85, March 1984.

29. Rupp JC, Suicidal garroting and manual self-strangulation. *J Forensic Sci* 15(1): 39-5, Jan. 1979.

30. Hansch CF, Throat-skeleton fractured by strangulation. *Z Rechtsmed* 79(2): 143-7, March, 1977.

31. Hocking FD, Hanging and manual strangulation. *Med Sci Law* 6(1): 49-1, Jan. 1966.

32. Srivastava AK, Das Gupta SM, Tripathi CB, A study of fatal strangulation cases in Varanasi (India). *Am J Forensic Med Pathol* 8(3): 220-4, Sept. 1987.

33. Luke JL, Reay DT, Eisele JW, Correlation of circumstances with pathological findings in asphyxial deaths by hanging: A prospective study of 61 cases from Seattle, Wash., *J Forensic Sci* 30(4): 1140-7, Oct. 1985.

34. Stanley RB, Hanson DG, Manual Stragulation Injuries of the Larynx. *Arch Otolaryngol* 109: 344-7, May 1983.

35. Patel F, Strangulation injuries in children. *The Journal of Trauma: Injury, Infections and Critical Care* 40(1): 68-72, Jan. 1996.

36. Perper JA, Sobel MN, Identification of fingernail markings in manual strangulation. *Am J Forensic Med Pathol* 2(1): 45-8, March 1981.

37. Starrs JE, Procedure in identifying fingernail imprint in human skin survives appellate review. *Am J Forensic Med Pathol* 6(2): 171-3, June 1985.

38. Harm T, Rais J, Types of injuries and inter-related conditions of victims and assailants in attempted and homicidal strangulation. *Forensic Sci Int* 18:101-23, 1981.

39. Ikeda N, Harada A, Suzuki T, Homicidal manual strangulation and multiple stun-gun injuries. *Am J Forensic Med Pathol* 13(4):23-32, 1992.

40. Harm T, Rajs J, Face and neck injuries due

to resuscitation versus throttling. *Forensic Sci Int* 12:109-15, 1983.

41. Jaffe FA, Petechial hemorrhages: A review of pathogenesis. *Am J Forensic Med Pathol* 15(3):203-7, Sept. 1994.

42. Luke JL, Strangulation as a method of homicide. *Arch Pathol* 83(1):64-70, Jan. 1967.

43. Maxeiner H, Mucosal hemorrhage of the larynx in strangulation and other causes of death. *Beitr Gerichtl Med* 47:429-35, 1989.

44. Stanley RB, Manual strangulation injuries of the larynx. *Arch Otolaryngol* 109(5):344-47, May 1983.

45. Gardel J, Injuries of the larynx. *Probl Actuels Otorhinolaryngol* 133-44, 1965.

46. Maxeiner H, Delayed death following strangulation. *Arch Kriminol* 180(5-6): 161-71, Nov. 1987. Zasshi NH, A case of phypoxic brain damage consequent to ligature strangulation. 43(2):186-90, April 1989. Kubo S, Ogata M, Iwasaki M, Kitamura O, Shimokawa I, Suyama H, Hironaka M, On the absence of cutaneous lesions of the neck in cases of strangulation. *Minerva Medicoleg* 87(6):299-02, Nov. 1967. Nathan, F, Italian. Case report. Delayed death after pressure on the neck: possible causal mechanisms for mode of death in manual strangulation discussed. *Forensic Sci Int* 78(3):193-97, April 1996. Anscombe AM, Late neuropathological consequences of strangulation. *Resuscitations* 15(3):171-85, Sept. 1987. Simpson RK Jr, Goodman JC, Rouah

E, Caraway N, Baskin DS. Strangulation as a Method of Homicide. *Arch Pathol* 83:64-70, Jan. 1967. Luke JL.

47. The relevance of battered women's syndrome evidence and the common experiences of battered women was initially defined by the criteria set out in *People v. Bledsoe* 36 Cal. 3d 236, 249-51, 1984.

48. Questions developed by Detective Mike Agnew from the Fresno Police Department with 20 years of experience working with victims of domestic violence.

49. Hyman A, Mandatory reporting of domestic violence, prepared for the Family Violence Prevention Fund.

50. *San Diego City Attorney Domestic Violence Prosecution Protocol* prepared by Casey Gwinn, 1989, and *Prosecuting Domestic Violence Cases without Victim Participation* by Gwinn.

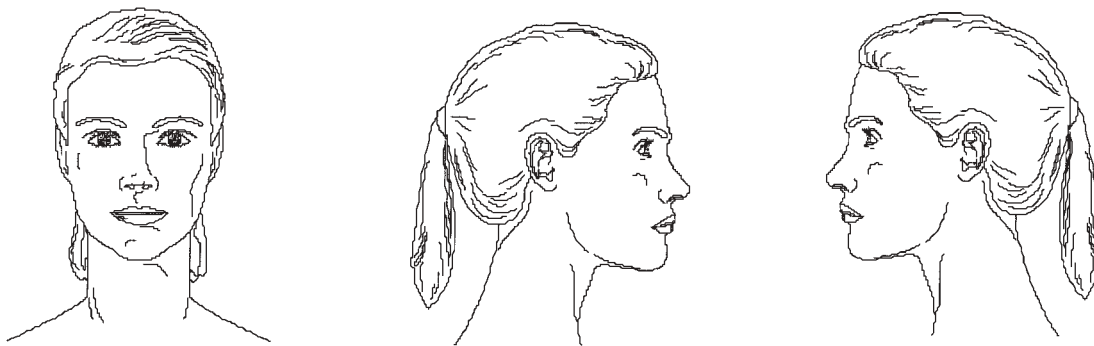
51. Recognition and Evaluation of Injuries in Victims of Domestic Violence (72-slide presentation, instructor test and 26-page manual) developed by Dr. William Smock and Dr. Sandleback. Slide Program is \$159. CD ROM, \$79.50; combo package \$185.50. For more information, send an email to domestic@kacep.org. A two-hour strangulation training video tape with accompanying materials in a CD is available through IMO Productions, Inc., at www.imoproductions.com or e-mail: imo@san.rr.com.

Documentation Chart for Attempted Strangulation Cases

Symptoms and/or Internal Injury:

Breathing Changes	Voice Changes	Swallowing Changes	Behavioral Changes	OTHER
Difficulty Breathing Hyperventilation Unable to breathe Other:	Raspy voice Hoarse voice Coughing Unable to speak	Trouble swallowing Painful to swallow Neck Pain Nausea Vomiting	Agitation Amnesia PTSD Hallucinations Combativeness	Dizzy Headaches Fainted Urination Defecation

Use face & neck diagrams to mark visible injuries:



Face	Eyes & Eyelids	Nose	Ear	Mouth
Red or flushed Pinpoint red spots (petechiae) Scratch marks	Petechiae to R and/or L eyeball (circle one) Petechiae to R and/or L eyelid (circle one) Bloody red eyeball(s)	Bloody nose Broken nose (ancillary finding) Petechiae	Petechiae (external and/or ear canal) Bleeding from ear canal	Bruising Swollen tongue Swollen lips Cuts/abrasions (ancillary finding)
Under Chin	Chest	Shoulders	Neck	Head
Redness Scratch marks Bruise(s) Abrasions	Redness Scratch marks Bruise(s) Abrasions	Redness scratch marks Bruise(s) Abrasions	Redness Scratch marks Finger nail impressions Bruise(s) Swelling Ligature mark	Petechiae (on scalp) Ancillary findings: Hair pulled Bump Skull fracture Concussion

Copyright: San Diego City Attorney's Office 2001. All rights reserved.

Used with permission by the San Diego City Attorney's Office.

Questions to ASK: Method and/or Manner:

How and where was the victim strangled?

One hand (R or L) Two hands Forearm (R or L) Knee/Foot

Ligature (Describe): _____

How long? _____ seconds _____ minutes Also smothered?

From 1 to 10, how hard was the suspect's grip? (Low): 1, 2, 3, 4, 5, 6, 7, 8, 9, 10 (high)

From 1 to 10, how painful was it? (Low): 1, 2, 3, 4, 5, 6, 7, 8, 9, 10 (high)

Multiple attempts: _____ Multiple methods: _____

Is the suspect **RIGHT** or **LEFT** handed? (Circle one)

What did the suspect say while he was strangling the victim, before and/or after?

Was she shaken simultaneously while being strangled? Straddled? Held against wall?

Was her head being pounded against wall, floor or ground?

What did the victim think was going to happen?

How or why did the suspect stop strangling her?

What was the suspect's demeanor?

Describe what suspect's face looked like during strangulation?

Describe prior incidents of strangulation? Prior domestic violence? Prior threats?

MEDICAL RELEASE

To All Health Care Providers: Having been advised of my right to refuse, I hereby consent to the release of my medical/dental records related to this incident to law enforcement, the District Attorney's Office and/or the City Attorney's Office.

Signature: _____ Date: _____

Copyright: San Diego City Attorney's Office 2001. All rights reserved.